

# Use of Coronary Computed Tomographic Angiography to Facilitate Percutaneous Coronary Intervention of Chronic Total Occlusions

## Abstract

**Background:** Chronic total occlusions (CTOs) in coronary arteries, affecting approximately 20% of patients with suspected coronary artery disease (CAD), pose challenges in intervention due to a lower success rate (55–80%) compared to conventional lesions (>90%). **This study aimed** to investigate whether multi detector computed tomography (MDCT) have an impact on the success rate of percutaneous coronary intervention (PCI) of CTO of coronary arteries. **Methods:** This was a prospective study included 100 patients divided into two equal groups of age from 18 - 80 years age groups and of both sexes presented to radiology department, Benha university hospital and national heart institute. **Results:** The use of contralateral injection was significantly higher in Group I (92%) compared to Group II (60%). The success rate of the procedure was significantly higher in Group I (94%) than in Group II (80%). Group I experiencing fewer complications (8.2%) compared to Group II (40.8%). Finally, Group I having a lower mean value of serum creatinine compared to Group II.. The multivariate model revealed that a history of MI was associated with about eight times increased risk of failure. The use of CT preprocedural was associated with 86.4% risk reduction of failure. **Conclusion:** Computed Tomography Coronary Angiography (CTCA) has facilitated the diagnosis of CAD by enabling accurate assessment of the anatomical features without the need for an invasive procedure. CTCA has its uses during the various steps of CTO PCI, starting from the initial diagnosis, followed by pre-interventional planning, and finally, post-procedure outcome and follow-up.

**Keywords:** Coronary Computed Tomographic Angiography; Chronic Total Occlusions; Percutaneous Coronary Intervention.

## **Introduction**

Coronary artery disease (CAD) is the most common cause of sudden death and is also the most common reason for death of men and women over 20 years of age (1).

This lesion subset is usually more difficult to be treated with percutaneous coronary intervention (PCI) than non-occlusive diseases. Various invasive and non-invasive imaging techniques are used for cardiac diagnosis. The most important techniques used are coronary angiography (CA), intravascular ultrasound, echocardiography, myocardial perfusion scanning & magnetic resonance imaging (2).

Coronary angiography (CA) is currently the standard technique to detect and evaluate coronary artery stenosis and is the basis for decision-making regarding further work-up. Recent technological advances in CA using the bi-plane technique and flat-panel detectors have contributed to further enhancing image quality and performance. For example, the newest catheter angiography systems provide 3D modeling of the coronary arteries based on simultaneous acquisition of two projections of the same artery (3).

Therefore, there is great interest in exploring new, non-invasive imaging modalities with less X-ray radiation, less direct interaction of the physician, and less hospital time for the patient. Of these new imaging modalities, Multislice computed tomography (MSCT) with the rapid and continuous developments in its structure and techniques over the past few years is considered now one of the most important diagnostic tools in evaluation of CAD up to an extent that made some interventional cardiologists consider it as a gatekeeper for invasive angiography (4).

Computed tomography coronary angiography (CTCA) is a robust and reliable non-invasive alternative imaging modality to invasive CA, which is the reference standard in evaluating the degree of coronary artery stenosis (5).

Percutaneous coronary intervention (PCI) for chronic total occlusion (CTO) is a challenging procedure with considerable variability in its success rates, and many attempts at improving CTO-PCI success rates have been made. Coronary computed tomography angiography (CTA) provides valuable information before and during CTO-

PCI, which is essential for the development of primary and secondary procedural plans that include risk and benefit assessments of the procedures (6).

The purpose of this study was to investigate whether multi detector computed tomography (MDCT) have an impact on the success rate of PCI of CTO of coronary arteries.

### **Patients and methods**

This was a prospective study designed to investigate whether MDCT have an impact on the success rate of PCI of CTO of coronary arteries.

The study included 100 patients divided into two equal groups of age from 18 -80 years age groups and of both sexes presented to radiology department, Benha university hospital and national heart institute.

An informed written consent was obtained from the patients. Every patient received an explanation of the purpose of the study and had a secret code number. The study was done after being approved by the Research Ethics Committee, Faculty of Medicine, Benha University. (This study was conducted from 2022 to 2023)

**Inclusion criteria** were chronic coronary occlusion in native coronary arteries with estimated duration >3 months old referred for evaluation of coronary arteries by multidetector CT angiography and conventional CA, chronic coronary occlusion of the native coronary arteries in patient with history of CABG, ongoing angina or a positive functional stress test and planned percutaneous revascularization to CTO.

**Exclusion criteria** were patients with known renal failure (estimated glomerular filtration rate <60 ml/min/1.73 m<sup>2</sup>) or contra-indications for CT-scanning such as a previous allergic reaction to contrast, irregular heart rate, i-stent stenosis, history of CABG ,the graft occlusion is excluded, any established cardiac or cerebrovascular disease, acute chest pain, age ≥80 years or ≤18 years, pregnancy, significant medical comorbidity, patients refusal, decompensated heart failure (NYHA class IIIb and IV) and history of severe contrast allergic reactions.

**Methodology:**

All patients were subjected to the following: **Patient History:** age (years), Dyslipidemia, DM, HTN, Smoking status, previous myocardial infarction, history of PCI History of CABG history of previous trial of CTO lesion. Clinical Examination: for signs of heart failure. Transthoracic echocardiography: for assessment of LV functions and detect any procedural complication during in-hospital stay. Serum creatinine: before MDCT and ICA then within one week after PCI to CTO. MDCT angiography of coronary arteries.

**Patient preparation:** Patients were given instruction as fasting 4-6 hours before scan but encourage water intake, avoid caffeine products, smoking & exercise 12 hours before scan, instructions how to control breathing and breath hold for few seconds (10-15 seconds), stop taking drugs used for pulmonary hypertension 48 hours before scan and skin preparation of the chest wall (hair removal in males)

**Premedication (Heart rate control):** The target heart rate below 65bpm was preceded directly to the scan. Those with resting heart rate ranging more than 65-70 bpm and their EF was more than 35% were given a cardioselective beta-blocker one hour prior to scan provided that there was no contraindication to its use, to obtain a stable low heart rate. If heart rate was still above 70 bpm, the examination was postponed to another setting. After heart rate control, 18g cannula was inserted into right antecubital vein for all patients, left upper limb cannulation was avoided and kept contrast warm at room temperature to avoid streak artifact from dense contrast material.

**Technique:** Patients lied supine with both arms above their head their feet entering the gantry first and they were positioned to ensure the heart lies in center of the gantry. Four ECG electrodes were placed on their chest after proper skin preparation and were connected by four leads to the CT trigger monitor. Patient received 5mg sublingual isosorbide dinitrate immediately prior to scan if no contraindication to its use. A breathing exercise was performed to measure the heart rate during breath holding period of 10 -15 seconds after which the scanner automatically adjusted the exposure window settings for optimal temporal resolution.

All examinations were performed by using Dual source 128-slice MDCT (GE, GE medical system ,country ) & Dual source 128-slice MDCT (SIEMENS, SIEMENS medical system, Germany).

An AP and lateral scout acquisition were obtained to determine the position of the heart and aortic arch and to define the scan range of coronary CTA which extended from just above the clavicles down to 1cm below the apex of the heart. The scanning direction was craniocaudal during a single inspiratory breath-hold, and the ECG signal was recorded simultaneously. Multidetector row helical CT was performed using retrospective ECG gating triggering. Dose parameters and contrast material volumes were selected according to patient size.

**Acquisition parameters:** 0.35sec gantry rotation time, variable Ma selected automatically by the scanner according to patient body habitus (range: 300-580mA), variable kV according to BMI; 100kV for BMI below 25Kg/m<sup>2</sup>, 120kV for BMI (25-32Kg/m<sup>2</sup>) and 135kV for higher BMI. scout from pulmonary apices to the heart.

**Scan extent:** ideally to be determined by calcium scoring Just below the tracheal bifurcation to below the heart.

**Contrast medium injection:** Non-ionic low-osmolality contrast media (Ultravist 370mgI/ml) was injected through the peripherally inserted IV cannula using dual head powered automatic injector followed by 50-60cc saline. The flow rate ranged from 4 to 6ml/sec while the amount of contrast material ranged from 65ml to 90ml. Automatic bolus tracking method was used to detect contrast media arrival at descending aorta; pre-monitoring slice (100mA, 120 kV) was obtained at main pulmonary artery level and a rounded ROI was placed at descending aorta with trigger threshold being set to 180HU. After taking the scout, and calcium score smart prep method was used to acquire the images (ascending aorta, threshold -100 HU). Bolus tracking was done. The time of the start of the helical scan after IV contrast administration was determined by Bolus tracking; when we start injection of contrast bolus and give around 10 seconds so contrast will reach root of aorta, we asked the patient to take deep breath and start acquisition.

**Method of acquisition:** Technique ECG-gated retrospective technique Slice thickness 0.625 mm Gantry rotation time 0.35 sec Pitch Variable Tube voltage 120 kv Tube current auto MA Kernal 30 Recon interval 0.625 mm Matrix  $512 \times 512$  All examinations were performed without complications.

**Image reconstruction:** The retrospective ECG-data was used for image reconstruction. Images were reconstructed with at 75% of R-R interval and also at the best diastolic phase. If motion artifacts were present, additional reconstructions in 5% increments and decrements of the R-R interval is performed. This included data sets reconstructed was in systole, if diastolic data sets showed motion artifact. If no data set entirely free of motion artifact, the data set with best image quality in the region of the graft was used for further analysis.

**Post processing:** The reconstructed images were transferred to a workstation to review axial images and also to obtain multi-planar reformatted images at sagittal and coronal planes. Also maximum intensity projection images, 3D volume rendered images, semitransparent 3D volume rendered images, volume rendered technique (VRT), curved MIP, and tree view projections were obtained for detailed assessment of coronary artery bypass grafts and lesion characterization if present.

**Image analysis:** Assessment of calcium score and assessment of image quality: According to quality of CT images, studies were classified into: Good quality; no motion artifacts, acceptable quality; mild motion artifacts with still diagnostic scan and poor quality; non-interpretable coronary artery lesions because of significant motion artifacts.

**Assessment of CTO lesions:** The obtained MDCT datasets were analyzed. The 3D volume rendered images were useful for global assessment of the location of CTO segments.

**Characters of the artery proximal to CTO and CTO segment, stump characteristics** tapered or blunt and, characters of the artery after the CTO then after collecting those data: CT derived J CTO score easy (0) intermediate (1 point) difficult (2 points) very difficult (3 or more) for categorization of difficulty of PCI.

## **Group 2 invasive coronary angiography as a pre-procedural decision of cto dsata:**

All patients underwent conventional invasive angiography as the standard of reference for the comparison of MSCT results. Biplanar conventional CA was performed by using the Seldinger technique via the femoral artery with a 6- or 7-F catheter. Visualization of the coronary arteries cto lesions data was performed according to standard projections. All studies were documented on video- tape for subsequent review. Angiograms were interpreted independently by cardiologists, who had performed the angiography, they calculated the J- CTO score using conventional CA data. CTO- PCI was performed by experienced operators at our institution. In line with previously published articles, the wire- crossing time was defined as the time from the initial insertion of the guidewire into the coronary lumen to the time of successful wire crossing beyond the lesion into the distal vessel. The strategy for CTO- PCI was selected according to lesion characteristics and operator preference. Procedural success was defined as post- PCI TIMI flow grade 3 and residual stenosis >30%. Comparison of success rate between the two groups is calculated.

**Approval code:** MD 4-3-2022

### **Statistical analysis**

Statistical analysis was done by SPSS v28 (IBM, Armonk, New York, United States). Quantitative data were assessed for normality using the Kolmogorov–Smirnov test and direct data visualization methods. According to normality, quantitative data were summarized as means and standard deviations or medians and ranges. Categorical data were summarized as numbers and percentages. Quantitative data were compared between the studied groups using the independent t-test or Mann-Whitney U test for normally and non-normally distributed quantitative variables, respectively. Categorical data were compared using the Chi-square or Fisher’s exact test. Univariate and multivariate logistic regression analysis was done to predict procedural failure. The odds ratios with 95% confidence intervals were calculated. All statistical tests were two-sided. P values less than 0.05 were considered significant.

## Case presentation

### Case (1)

#### ❖ History:

Male patient 58-year-old HTN and DM ex-smoker complaining left shoulder pain on effort and at sleep not improved on anti-ischemic treatment ,not atypical chest pain, described as chest discomfort

#### ❖ Echocardiography

- ❖ Revealed that EF 50% with regional wall motion abnormality apical and adjoining segments.
- ❖ Classified as intermediate risk and referred to us for CT coronary angiography.
- ❖ Diagnosis: -by CT angiography

#### Left anterior descending artery (LAD):

- The Mid LAD, after giving D2 shows long (about 3 cm in length) severely diseased segment of mixed plaque causing total occlusion. Fig 1a fig 1b
- **Distally the LAD appears markedly attenuated caliber with poor opacification. Fig1 c**
- **Diagnosed as Mid LAD long segment of total occlusion (CAD-RAD 5) and J CTO score (2 points) (difficult).**
- ***By convetional angiography:*** confirmed data of CT coronary angiography.
- ❖ Percutaneous intervention for CTO was done.
- ❖ Result:

**Success of PCI with no complications, time consumed about 45 min 250 ml contrast.**

#### ❖ Pre-procedural CT findings fig 1a toto fig 1e

### Case (2)

#### ❖ History:

Male patient 54-year-old HTN and DM, history of CABG since 2017 At 1/2022 PCI to LCX ,Only patent LIMA to LAD occluded other 2 grafts and failed trial PCI to correct CTO of RCA.



- ❖ Referred to us for CT coronary angiography to delineate the course of RCA .

**Diagnosis:**

*by CT angiography*

**Right coronary artery (RCA):**

- **RCA:** Shows long segment non calcified plaques at distal course extending to PDA exerting **total occlusion** its length about 3 cm, bending angle >45.
- **PDA is occluded and attenuated (negative remodeling).**
- **Diagnosed as distal RCA and whole PDA long segment of total occlusion (CAD-RAD 5) and J CTO score (3 points) (difficult).**

- ❖ **Result:**

**Failure of PCI with dissection time consumed about 1.5 hours 300 ml contrast.**

## **Results**

Smoking status significantly differed between the studied groups, with a higher prevalence in Group II (70%) compared to Group I (50%), history of previous trials showed a significant difference, with 32% in Group II and only 6% in Group I, which was highly significant. There was no significant differences regarding age, sex, diabetes mellitus, hypertension, dyslipidemia, history of PCI, history of CABG, history of MI, and CT derived J CTO score (Table 1).

Preprocedural MSCT findings in Group I: The Coronary Artery (CA) median was 117. The distribution of CTO segments was predominantly in the proximal location (48%), followed by mid (30%), distal (12%), and ostial (10%) segments. Regarding the CTO vessel involvement, the Right Coronary Artery (RCA) was most affected (58%), followed by the Left Anterior Descending artery (LAD, 32%) and the Left Circumflex artery (LCX, 10%). The majority of CTOs were greater than 20 mm in length (74%). Stump characteristics showed a higher prevalence of tapered stumps (60%) over blunt (40%). Calcification was a common feature, with 38% showing proximal cap calcification, predominantly eccentric (84.2%), and 40% having distal cap calcification,

evenly split between circumferential and eccentric types. Calcification in the center of the vessel was noted in 38% of cases, and dense calcifications were present in 40%. Notably, 52% had a side branch at CTO entry, and the bending angle was evenly distributed between greater and less than 45 degrees. In terms of the artery distal to the CTO, 66% were diseased, while 34% were not. Sizable collaterals were present in 28% of cases. The TIMI flow grade was predominantly TIMI 0 (92%), with only a small fraction showing TIMI I flow (8%) (Table 2).

Preprocedural conventional angiography findings in Group II: Plaque calcification was highly prevalent, observed in 78% of the cases. The Right Coronary Artery (RCA) was the most affected vessel, involved in 52% of cases, followed by the Left Anterior Descending (LAD) artery (38%) and the Left Circumflex (LCX) artery (10%). The CTO segments were most frequently located in the proximal (46%) and mid (30%) portions of the vessels, with fewer occurrences in the distal (18%) and ostial (6%) segments. The length of the CTO was predominantly greater than 20 mm, accounting for 80% of the cases. Regarding the stump characteristics, the majority (62%) had tapered stumps, while 38% had blunt stumps. Calcification at the proximal cap was present in 46% of the cases and at the distal cap in 50%. Two-thirds (66%) of cases had a side branch at the CTO entry. The bending angle of the CTOs was slightly more often greater than 45 degrees (54%) than less (46%). In terms of the artery distal to the CTO, 72% were found to be diseased, while 28% were not. Sizable collaterals were present in 30% of the cases. Regarding TIMI flow, 66% of cases were categorized as TIMI 0 and 34% as TIMI I (Table 3).

Univariate logistic regression analysis was done for the prediction of procedure failure. Significant predictors on the univariate level were history of MI (OR = 3.558, 95% CI = 1.006 – 12.584, P = 0.049) and using CT before the procedure (OR = 0.255, 95% CI = 0.066 - 0.992, P = 0.049). Significant variables on the univariate level were included in a multivariate analysis. The multivariate model revealed that a history of MI was associated with about 8 times increased risk of failure (OR = 7.501, 95% CI = 1.595 – 35.296, P = 0.011). Moreover, the use of CT preprocedural was associated with 86.4% risk reduction of failure (OR = 0.136, 95% CI = 0.027 – 0.676) (Table 4).

## Discussion

In the present study smoking status significantly differed between the studied groups, with a higher prevalence in Group II (70%) compared to Group I (50%) (P-value = 0.041). Additionally, the history of previous trials showed a significant difference, with 32% in Group II and only 6% in Group I, which was highly significant (P < 0.001). On the other hand, several variables were found to be not statistically significant, including age (P = 0.411), sex (P = 0.334), diabetes mellitus (P = 0.534), hypertension (P = 0.391), dyslipidemia (P = 1), history of PCI (P = 0.069), history of CABG (P = 0.668), history of MI (P = 0.037), and CT derived J CTO score (P = 0.347).

These results are similar to Gue et al., who undertook their study on 74 CTO patients with successful PCI in 77% of patients and found that the patient's age, DM, HTN, and dyslipidemia had no significant effect on procedure outcome (7).

In line with demographic findings, Mehta et al. Analysis of 146 CTO patients and out of these, 105 patients (72%) (mean age: 58.65 ± 10.14 years) had successful PCI and was unsuccessful in 41 patients (28%) (mean age: 62.87 ± 12.12 years). The baseline demographic and clinical characteristics of the patients with successful and unsuccessful CTO PCI exhibited no significant difference between the two groups (8).

Regarding Preprocedural MSCT findings in Group I and conventional angiography findings in Group II: In the preprocedural imaging assessments, Group I, utilizing MDCT, exhibited diverse findings indicative of the coronary CTO landscape. The Coronary Artery (CA) score ranged widely (0 to 971) with a median of 117, emphasizing the variability in disease severity. CTO segments were predominantly located proximally (48%) and often extended beyond 20 mm in length (74%). Right Coronary Artery (RCA) involvement was prevalent (58%), followed by the Left Anterior Descending artery (LAD, 32%) and the Left Circumflex artery (LCX, 10%).

Stump characteristics revealed a higher prevalence of tapered stumps (60%), with calcification patterns including proximal cap calcification (38%), often eccentric (84.2%), and distal cap calcification (40%), evenly distributed between circumferential and

eccentric types. Notably, 52% had a side branch at CTO entry, and the majority (66%) of arteries distal to the CTO were diseased. In contrast, Group II, assessed through conventional angiography, showcased a high prevalence of plaque calcification (78%) and a CTO landscape predominantly located in proximal (46%) and mid (30%) vessel portions. The length of CTOs was mostly greater than 20 mm (80%), with a majority having tapered stumps (62%). Calcification at the proximal (46%) and distal (50%) caps, a side branch at CTO entry (66%), and a bending angle greater than 45 degrees (54%) were observed. Additionally, the majority of arteries distal to the CTO were diseased (72%), and TIMI flow predominantly scored as TIMI 0 (66%). These distinctive imaging characteristics provide valuable insights into the anatomical variations and disease patterns influencing the subsequent PCI outcomes in each group.

Regarding procedural findings in the studied groups: The use of contralateral injection was significantly higher in Group I (92%) compared to Group II (60%), with a P-value of <0.001.

In the current work, the use of contralateral injection was significantly higher in the MDCT group compared to conventional (92% vs. 60%, P-value <0.001).

Interestingly, Kim et al. indicated in their study that increasing the injection of contrast medium offered greater coverage during a single breath hold and reduced motion and partial volume artifacts. This can improve the quality of three-dimensional images generated from the CT data. Specifically, the advantages of using multidetector row CT include thinner section imaging, faster scanning, and improved longitudinal spatial resolution compared to single-detector row helical CT (9).

A study concluded that MDCT angiography holds significant diagnostic value compared to the reference standard test. Challenges for CTA in this area encompass the need for a substantial contrast injection (120–160 ml), limitations in speed coverage (recommended not to exceed 50 mm/s to prevent image acquisition from outpacing the contrast column), and the necessity for post-processing due to the considerable number of acquired slices, making it impractical to manage solely through viewing axial images (10).

In contrast, several variables did not show significant differences, including the approach ( $P = 0.669$ ), the number of wires used ( $P = 0.223$ ), the OTW device microcatheter and balloon usage ( $P = 0.814$ ), the number of stents ( $P = 0.982$ ), the procedure time ( $P = 0.223$ ), and the contrast volume used ( $P = 0.706$ ).

In terms of postprocedural findings in the studied groups: The success rate of the procedure was significantly higher in Group I (94%) than in Group II (80%), with a P-value of 0.037. Additionally, the incidence of complications was markedly different, with Group I experiencing fewer complications (8.2%) compared to Group II (40.8%), reflected in a P-value of  $<0.001$ . Finally, the mean serum creatinine levels showed a significant difference, with Group I having a lower mean value ( $1.24 \pm 0.31$  mg/dl) compared to Group II ( $1.36 \pm 0.4$  mg/dl) ( $P$ -value = 0.044). In contrast, causes of failure ( $P = 1.0$ ) and TIMI grades ( $P = 1$ ) did not significantly differ between groups.

In agreement with our results, Rolf et al., in their study titled Preprocedural Coronary CT angiography significantly improves success rates of PCI for CTO, compared 30 patients who had CTCA prior to CTO PCI with 45 patients who did not and found PCI success rate in 30 patients who underwent pre-procedural CTA was significantly higher than in patients without prior coronary CTA [unmatched: CT 90 % (27/30) vs. no CT 63 % (27/43),  $p = 0.009$ ; matched: CT 88 % (22/25) vs. no CT 64 % (16/25)  $p = 0.03$ ]. Through information not readily seen on invasive coronary, CA CTA can significantly enhance success rates of PCI for CTO (11).

Furthermore, Yokoyama et al., in their study of the impact of 16-slice computed tomography in PCI of CTO, investigated the use of CTCA prior to CTO intervention. Twenty-three angiographic CTO in 22 patients (mean age  $69 \pm 5$  years, 17 males) were included. All patients had undergone MSCT prior to PCI. Images were analyzed for lesion visibility and plaque characteristics of CTO. They found that overall procedural success was obtained in 21 CTOs (91.3%). MSCT can accurately identify the route of the CTO segment and evaluate both the distribution and amount of the calcified plaque within it. Even with the complicated and/or calcified lesions, the PCI success rate was excellent under MSCT guidance (12).

Univariate logistic regression analysis was done for the prediction of procedure failure. Significant predictors on the univariate level were history of MI (OR = 3.558, 95% CI = 1.006 – 12.584, P = 0.049) and using CT before the procedure (OR = 0.255, 95% CI = 0.066 - 0.992, P = 0.049). Significant variables on the univariate level were included in a multivariate analysis. The multivariate model revealed that a history of MI was associated with about eight times increased risk of failure (OR = 7.501, 95% CI = 1.595 – 35.296, P = 0.011). Moreover, the use of CT preprocedural was associated with 86.4% risk reduction of failure (OR = 0.136, 95% CI = 0.027 – 0.676).

In flow with our findings, Hong et al. conducted a trial to test whether success rates of CTO-PCI increased when including pre-procedural CCTA as part of the treatment regimen and found that pre-procedural coronary CTA-guidance for CTO resulted in higher success rates with numerically fewer immediate periprocedural complications such as coronary perforations or periprocedural myocardial infarction than angiography guidance. Higher success rates were more prominently observed in patients with CTO who had a high J-CTO score than those who did not (6).

## **Conclusion**

In conclusion, our study demonstrates that CTCA has facilitated the diagnosis of CAD by enabling accurate assessment of the anatomical features without the need for an invasive procedure. It is a rapidly advancing technology with new-generation scanners providing greater resolution, better quality images, and lower levels of radiation exposure. CTO is a frequent finding in CT image analysis. Successful revascularization of CTO with PCI results in improvements in patient outcomes and better left ventricular function while reducing the need for CABG. CTCA has its uses during the various steps of CTO PCI, starting from the initial diagnosis, followed by pre-interventional planning, and finally, post-procedure outcome and follow-up.

## **Sources of funding**

This research did not receive any specific grant from funding agencies in the public, commercial, or not-for-profit sectors.

**Author contribution**

Authors contributed equally in the study.

**Conflicts of interest**

No conflicts of interest

## References

1. Vähätalo J, Holmström L, Pakanen L, Kaikkonen K, Perkiömäki J, Huikuri H, et al. Coronary Artery Disease as the Cause of Sudden Cardiac Death Among Victims < 50 Years of Age. *Am J Cardiol.* 2021;147:33-8.
2. Malaiapan Y, Leung M, White AJ. The role of intravascular ultrasound in percutaneous coronary intervention of complex coronary lesions. *Cardiovasc Diagn Ther.* 2020;10:1371-88.
3. Giusca S, Schütz M, Kronbach F, Wolf D, Nunninger P, Korosoglou G. Coronary Computer Tomography Angiography in 2021-Acquisition Protocols, Tips and Tricks and Heading beyond the Possible. *Diagnostics (Basel).* 2021;11.
4. Hussain S, Mubeen I, Ullah N, Shah S, Khan BA, Zahoor M, et al. Modern Diagnostic Imaging Technique Applications and Risk Factors in the Medical Field: A Review. *Biomed Res Int.* 2022;2022:5164970.
5. Ngam PI, Ong CC, Chai P, Wong SS, Liang CR, Teo LLS. Computed tomography coronary angiography - past, present and future. *Singapore Med J.* 2020;61:109-15.
6. Hong SJ, Kim BK, Cho I, Kim HY, Rha SW, Lee SH, et al. Effect of Coronary CTA on Chronic Total Occlusion Percutaneous Coronary Intervention: A Randomized Trial. *JACC Cardiovasc Imaging.* 2021;14:1993-2004.
7. Guo L, Lv HC, Huang RC. Percutaneous Coronary Intervention in Elderly Patients with Coronary Chronic Total Occlusions: Current Evidence and Future Perspectives. *Clin Interv Aging.* 2020;15:771-81.
8. Mehta AB, Mehta N, Chhabria R, Mandurke V, Tawade N, Jain N, et al. Predictors of success in percutaneous Coronary intervention for chronic total occlusion. *Indian Heart J.* 2018;70 Suppl 3:S269-s74.



9. Kim JK, Park SY, Kim HJ, Kim CS, Ahn HJ, Ahn TY, et al. Living donor kidneys: usefulness of multi-detector row CT for comprehensive evaluation. *Radiology*. 2003;229:869-76.
10. Burrill J, Dabbagh Z, Gollub F, Hamady M. Multidetector computed tomographic angiography of the cardiovascular system. *Postgrad Med J*. 2007;83:698-704.
11. Rolf A, Werner GS, Schuhbäck A, Rixe J, Möllmann H, Nef HM, et al. Preprocedural coronary CT angiography significantly improves success rates of PCI for chronic total occlusion. *The International Journal of Cardiovascular Imaging*. 2013;29:1819-27.
12. Yokoyama N, Yamamoto Y, Suzuki S, Suzuki M, Konno K, Kozuma K, et al. Impact of 16-slice computed tomography in percutaneous coronary intervention of chronic total occlusions. *Catheterization and Cardiovascular Interventions*. 2006;68:1-7.

**Table (1) General characteristics of the studied groups**

		<b>Group I (n = 50)</b>	<b>Group II (n = 50)</b>	<b>P-value</b>
<b>Age (years)</b>	Mean $\pm$ SD	57 $\pm$ 8	58 $\pm$ 9	0.411
<b>Sex</b>				
Males	n (%)	37 (74)	41 (82)	0.334
Females		13 (26)	9 (18)	
<b>Diabetes mellitus</b>	n (%)	30 (60)	33 (66)	0.534
<b>Hypertension</b>	n (%)	32 (64)	36 (72)	0.391
<b>Dyslipidemia</b>	n (%)	40 (80)	40 (80)	1
<b>Smoking</b>	n (%)	25 (50)	35 (70)	<b>0.041*</b>
<b>History of PCI</b>	n (%)	17 (34)	26 (52)	0.069
<b>History of previous trial</b>	n (%)	3 (6)	16 (32)	<b>&lt;0.001*</b>
<b>History of CABG</b>	n (%)	17 (34)	15 (30)	0.668
<b>History of MI</b>	n (%)	13 (26)	5 (10)	<b>0.037*</b>
<b>CT derived J CTO score</b>				
Easy	n (%)	4 (8)	1 (2)	0.347
Intermediate	n (%)	5 (10)	2 (4)	
Difficult	n (%)	7 (14)	8 (16)	
Very difficult	n (%)	34 (68)	39 (78)	

\*Significant P-value; SD: Standard Deviation; PA: for Pulmonary Artery; PCI: Percutaneous Coronary Intervention; CABG: Coronary Artery Bypass Grafting; MI: Myocardial Infarction; CT: Computed Tomography; J CTO: Japanese Chronic Total Occlusion.

**Table (2) Preprocedural MSCT findings in Group I**

<b>Preprocedural MSCT findings</b>		
<b>CA score</b>	Median (range)	117 (0 - 971)
<b>CTO segment</b>		
Proximal	n (%)	24 (48)
Mid	n (%)	15 (30)
Distal	n (%)	6 (12)
Ostial	n (%)	5 (10)
<b>CTO vessel</b>		
LAD	n (%)	16 (32)
LCX	n (%)	5 (10)
RCA	n (%)	29 (58)
<b>CTO length</b>		
< 20 mm	n (%)	13 (26)
> 20 mm	n (%)	37 (74)
<b>Stump characteristics</b>		
Blunt	n (%)	20 (40)
Tapered	n (%)	30 (60)
<b>Proximal cap calcification</b>	n (%)	19 (38)
<b>Proximal cap degree of calcification</b>		
Circumferential	n (%)	3 (15.8)
eccentric	n (%)	16 (84.2)
<b>Distal cap calcification</b>	n (%)	20 (40)
<b>Distal cap degree of calcification</b>		
Circumferential	n (%)	10 (50)
Eccentric	n (%)	10 (50)
<b>Calcification in the center of the vessel</b>	n (%)	19 (38)
<b>calcifications &gt; 2/3 of circumference</b>	n (%)	16 (32)
<b>Dense calcifications</b>	n (%)	20 (40)
<b>Side branch at CTO entry</b>	n (%)	26 (52)
<b>Bending angle</b>		
> 45	n (%)	24 (48)
< 45	n (%)	26 (52)
<b>Artery distal to CTO</b>		
Diseased	n (%)	33 (66)
Not diseased	n (%)	17 (34)
<b>Sizable collaterals</b>	n (%)	14 (28)
<b>TIMI flow</b>		
TIMI 0	n (%)	46 (92)
TIMI I	n (%)	4 (8)

CA: Coronary artery; CTO: Chronic total occlusion; LAD: Left anterior descending artery; LCX: Left circumflex artery; RCA: Right coronary artery; TIMI: Thrombolysis in myocardial infarction

**Table (3) Preprocedural conventional angiography findings in group II.**

	<b>n (%)</b>
<b>Plaque calcification</b>	39 (78)
<b>Vessel affected</b>	
LAD	19 (38)
LCX	5 (10)
RCA	26 (52)
<b>CTO segment</b>	
Proximal	23 (46)
Mid	15 (30)
Distal	9 (18)
Ostial	3 (6)
<b>CTO vessel</b>	
LAD	19 (38)
LCX	5 (10)
RCA	26 (52)
<b>CTO length</b>	
< 20 mm	10 (20)
> 20 mm	40 (80)
<b>Stump characteristics</b>	
Blunt	19 (38)
Tapered	31 (62)
<b>Proximal cap calcification</b>	23 (46)
<b>Distal cap calcification</b>	25 (50)
<b>Side branch at CTO entry</b>	33 (66)
<b>Bending angle</b>	
> 45	27 (54)
< 45	23 (46)
<b>Artery distal to CTO</b>	
Diseased	36 (72)
Not diseased	14 (28)
<b>Sizable collaterals</b>	15 (30)
<b>TIMI flow</b>	
TIMI 0	33 (66)
TIMI I	17 (34)

LAD: Left anterior descending artery; LCX: Left circumflex artery; RCA: Right coronary artery; CTO: Chronic total occlusion; TIMI: Thrombolysis in myocardial infarction.

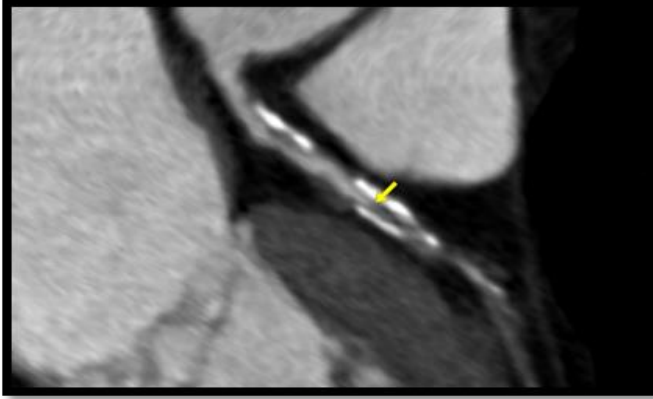**Table (4) Univariate and multivariate logistic regression analysis to predict procedural failure**

	Univariate		Multivariate	
	OR (95% CI)	P-value	OR (95% CI)	P-value
<b>Age (years)</b>	0.968 (0.905 - 1.034)	0.332	-	-
<b>Sex</b>	0.609 (0.125 - 2.979)	0.54	-	-
<b>Diabetes mellitus</b>	3.702 (0.773 - 17.73)	0.101	-	-
<b>Hypertension</b>	0.72 (0.216 - 2.405)	0.593	-	-
<b>Dyslipidemia</b>	0.333 (0.096 - 1.161)	0.085	-	-
<b>Smoking</b>	4.265 (0.892 - 20.401)	0.069	-	-
<b>History of PCI</b>	0.806 (0.244 - 2.662)	0.723	-	-
<b>History of previous trial</b>	0.319 (0.039 - 2.621)	0.288	-	-
<b>History of CABG</b>	0.937 (0.265 - 3.304)	0.919	-	-
<b>History of MI</b>	3.558 (1.006 - 12.584)	<b>0.049*</b>	7.501 (1.594 - 35.296)	<b>0.011*</b>
<b>Very difficult procedure</b>	1.27 (0.322 - 5.013)	0.733	-	-
<b>CT before procedure</b>	0.255 (0.066 - 0.992)	<b>0.049*</b>	0.136 (0.027 - 0.676)	<b>0.015*</b>

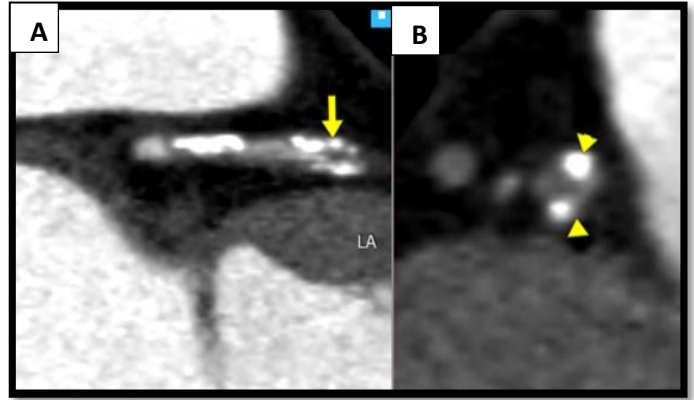
OR: Odds Ratio; CI: Confidence Interval; PCI: Percutaneous Coronary Intervention; CABG: Coronary Artery Bypass Grafting; MI: Myocardial Infarction.

## Case 1 Figure 1

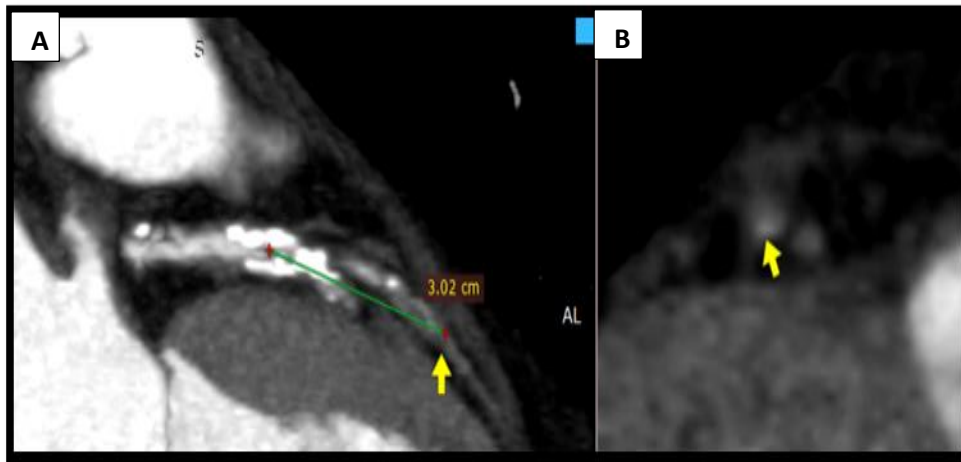
### ❖ Pre-procedural CT findings



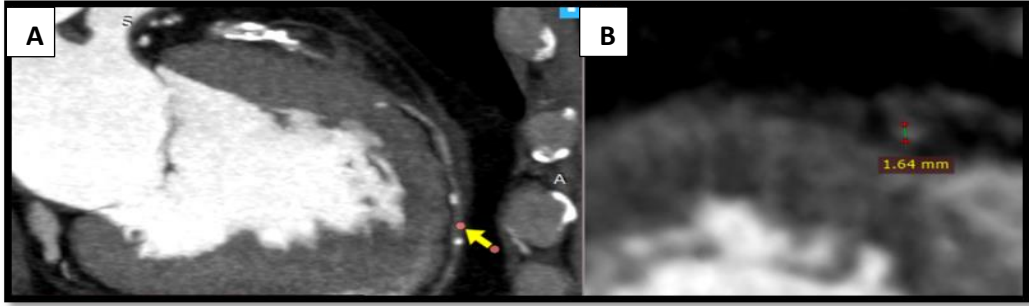
**Fig 1a** .Proximal stump: (tapered) arrow



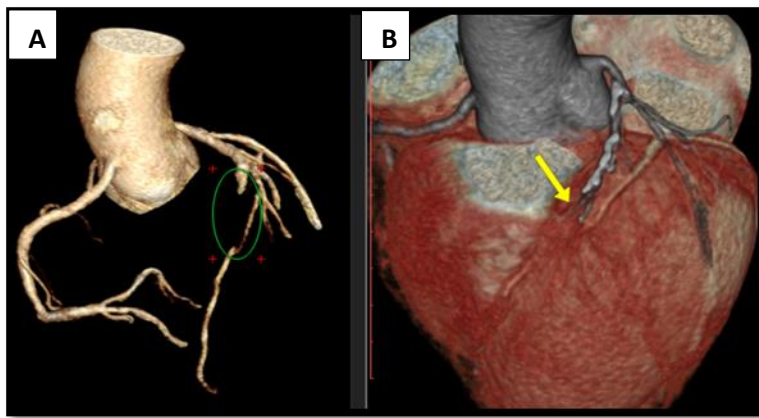
**Fig 1b: A.** Proximal cap calcifications (arrow) **B.** Eccentric dense calcifications <math><2/3</math> circumference (arrow heads)



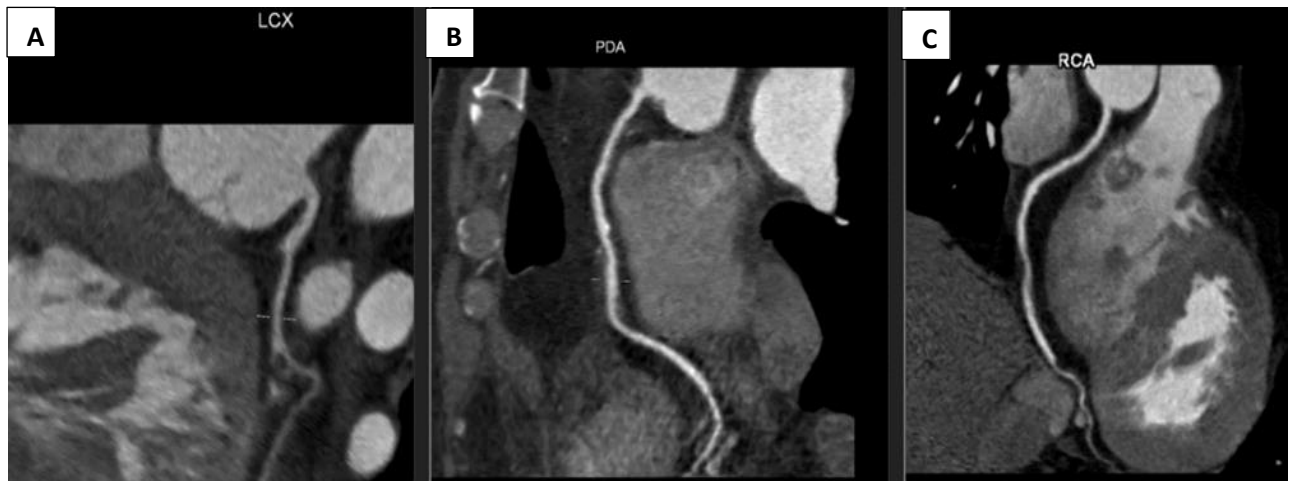**Fig 1c: A.**CTO length about 3 cm **B.**Distal cap shows no calcifications arrow



**Fig 1d:** Diseased distal LAD with attenuated caliber A.(curved MPR) B.axial



**Fig 1e:** LAD non opacified segment A .tree VR B.3D VRT heart



**Fig 1f :**Rest of the vessels (a)LCX shows no significant lesions (b)PDA normal (c)Mid RCA mild lesion



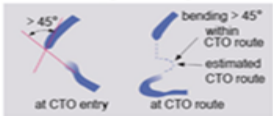

J-CTO SCORE SHEET		Version 1.0
Variables and definitions		
<p><b>Tapered</b></p> 	<p><b>Blunt</b></p> <p>Entry with any tapered tip or dimple indicating direction of true lumen is categorized as "tapered".</p>	<p><b>Entry shape</b></p> <p><input checked="" type="checkbox"/> Tapered (0)</p> <p><input type="checkbox"/> Blunt (1)</p> <p>point</p>
<p><b>Calcification</b></p> 	<p>Regardless of severity, 1 point is assigned if any evident calcification is detected within the CTO segment.</p>	<p><b>Calcification</b></p> <p><input type="checkbox"/> Absence (0)</p> <p><input checked="" type="checkbox"/> Presence (1)</p> <p>point</p>
<p><b>Bending &gt; 45 degrees</b></p> 	<p>One point is assigned if bending &gt; 45 degrees is detected within the CTO segment. Any tortuosity separated from the CTO segment is excluded from this assessment.</p>	<p><b>Bending &gt; 45°</b></p> <p><input checked="" type="checkbox"/> Absence (0)</p> <p><input type="checkbox"/> Presence (1)</p> <p>point</p>
<p><b>Occlusion length</b></p> 	<p>Using good collateral images, try to measure "true" distance of occlusion, which tends to be shorter than the first impression.</p>	<p><b>Occl.Length</b></p> <p><input type="checkbox"/> &lt; 20 mm (0)</p> <p><input checked="" type="checkbox"/> ≥ 20 mm (1)</p> <p>point</p>
<p><b>Re-try lesion</b></p> <p>Is this Re-try (2nd attempt) lesion? (previously attempted but failed)</p>		<p><b>Re-try lesion</b></p> <p><input checked="" type="checkbox"/> No (0)</p> <p><input type="checkbox"/> Yes (1)</p> <p>point</p>
<p>Category of difficulty (total point)</p> <p><input type="checkbox"/> easy (0)    <input type="checkbox"/> Intermediate (1)</p> <p><input checked="" type="checkbox"/> difficult (2)    <input type="checkbox"/> very difficult (≥ 3)</p>		<p><b>Total</b></p> <p><b>2</b> points</p>

Fig 1g: CT derived J CTO score 2 points (difficult)

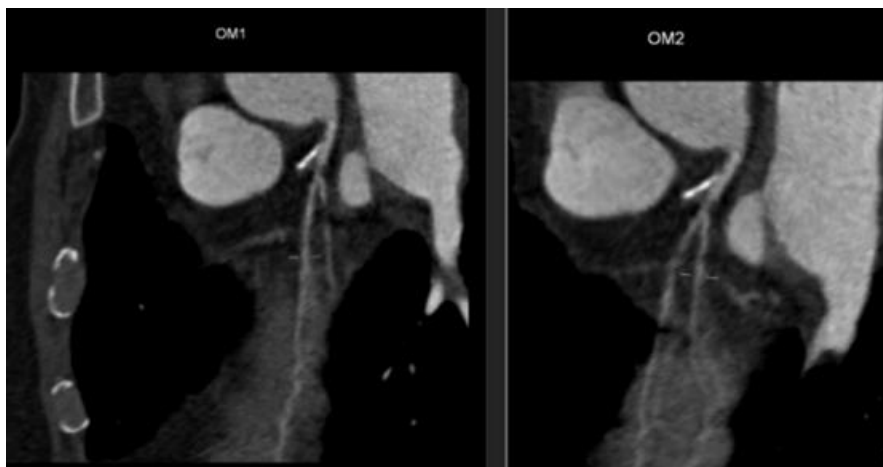
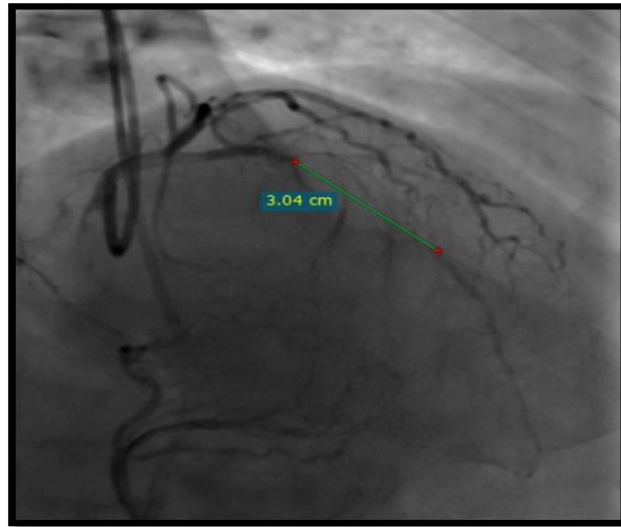


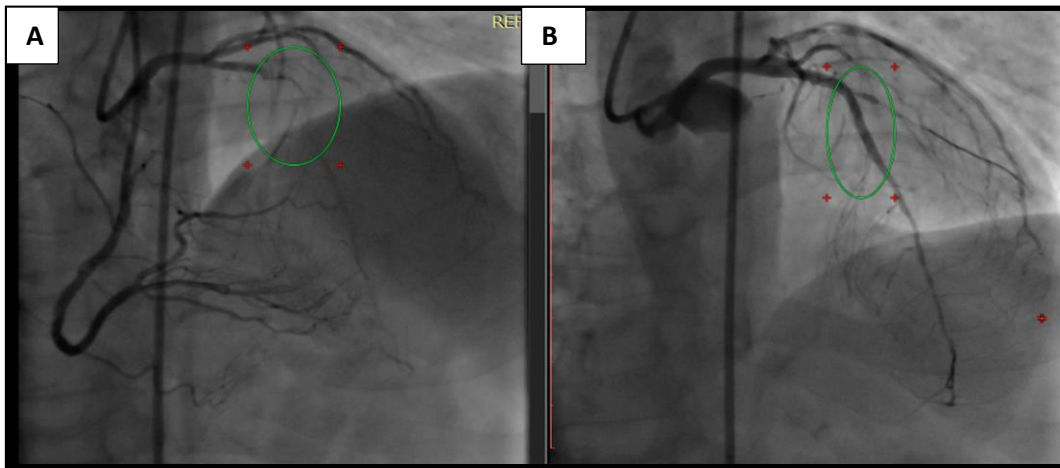
Fig 1h: OM branches show no significant lesions





**Fig 1i:** Dual injection in angiography to detect the CTO length

**Percutaneous intervention for CTO**



**Fig 1j:**A. Pre intervention and B.after success

## Case 2 Figure 2

### ❖ Pre-procedural CT findings

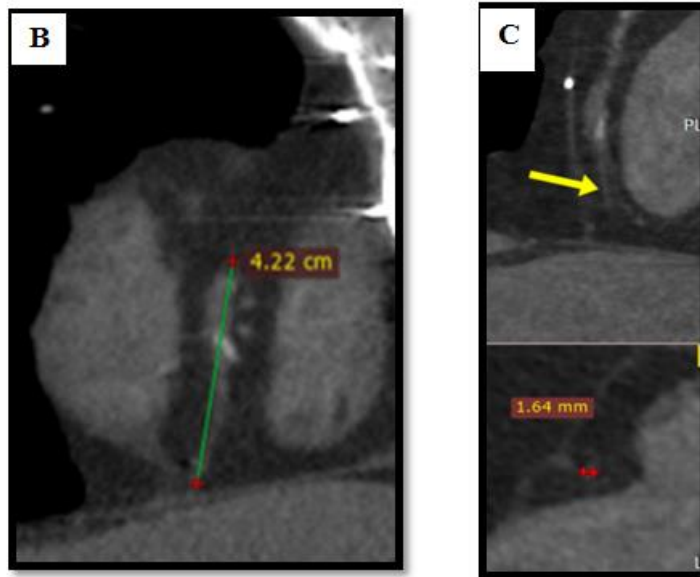
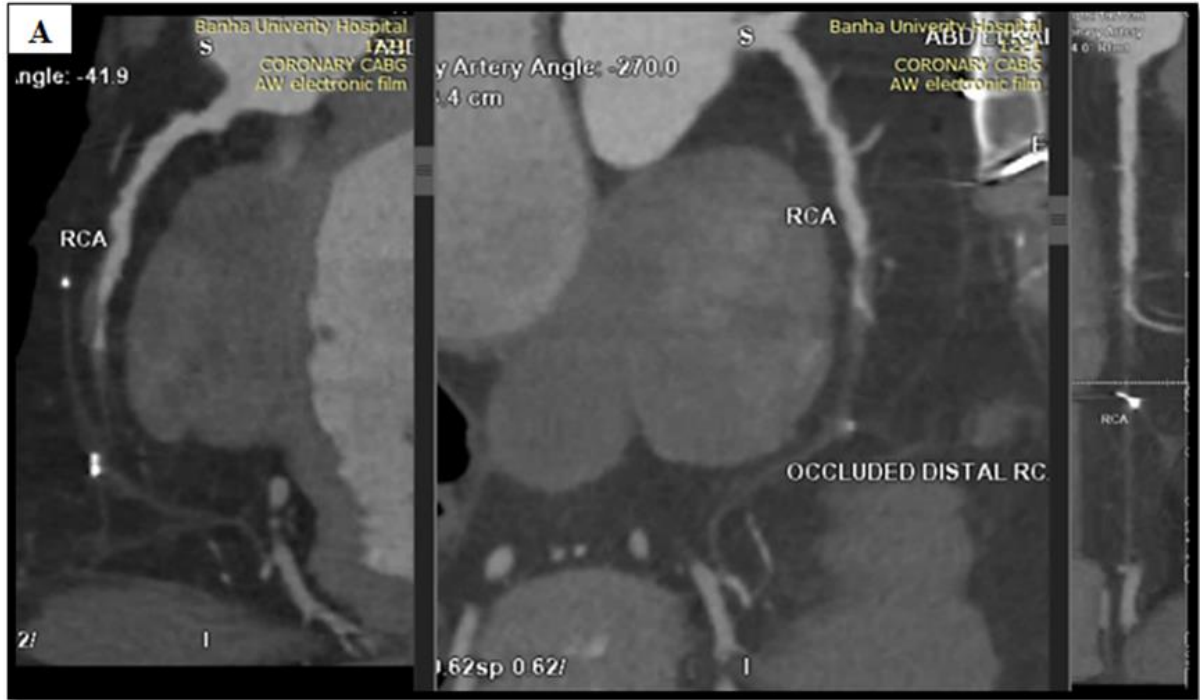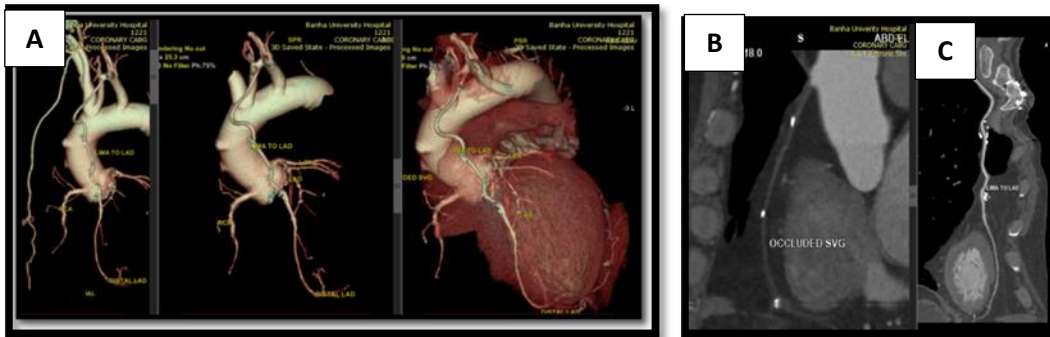
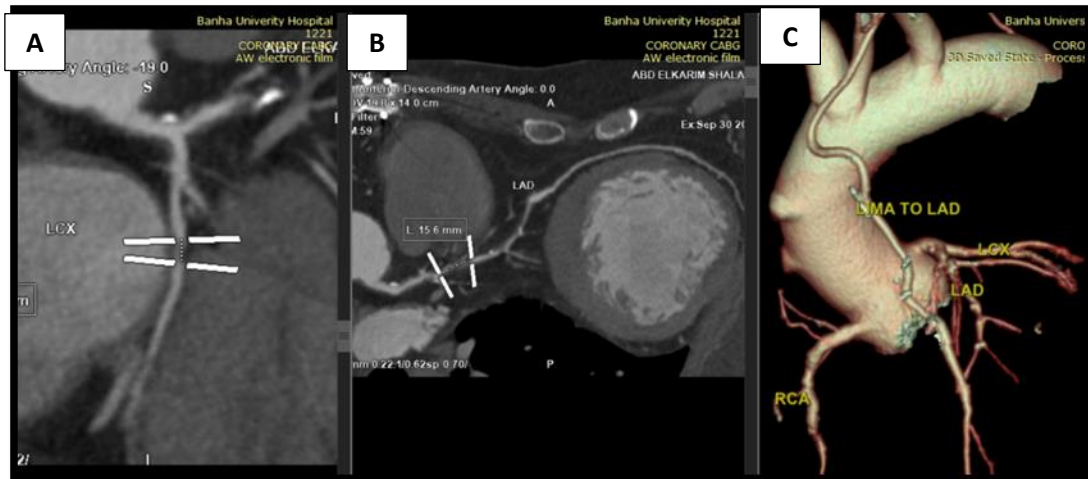


Fig 2 . Distal RCA CTO segment

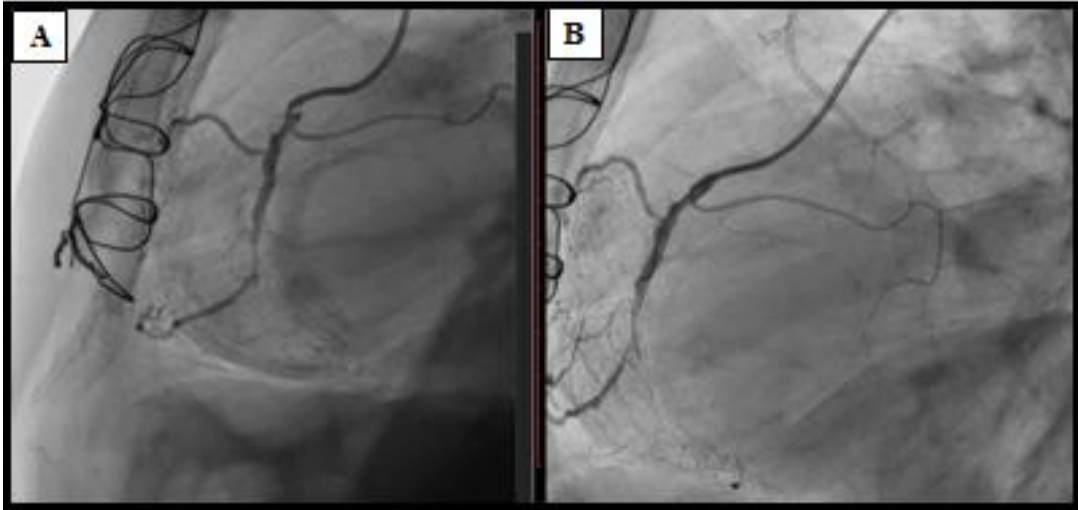- ❖ (A).Proximal stump :blunt ,,,Proximal cap calcifications : no
- ❖ (B) Length: 42 mm (>20mm)
- ❖ (C) curved MPR images shows the absence of distal RCA. Attenuated lumen about 1.6 mm arrow in image.



grafts finding (A) 3 images VR images of grafts and heart (B) occluded SVG to PDA (C) patent LIMA to LAD



Rest of the coronary arteries . (A) LCX mid mild lesion LAD. (B) Proximal LAD subtotal occlusion (C) volume rendered images of LCX and proximal LAD



Pre intervention RCA CTO C. after failure of crossing intervention